



First data on in vitro fertilization and blastocyst formation after intraovarian injection of calcium gluconate-activated autologous platelet rich plasma

E. Scott Sills, Natalie S. Rickers, Xiang Li & Gianpiero D. Palermo

To cite this article: E. Scott Sills, Natalie S. Rickers, Xiang Li & Gianpiero D. Palermo (2018): First data on in vitro fertilization and blastocyst formation after intraovarian injection of calcium gluconate-activated autologous platelet rich plasma, Gynecological Endocrinology, DOI: [10.1080/09513590.2018.1445219](https://doi.org/10.1080/09513590.2018.1445219)

To link to this article: <https://doi.org/10.1080/09513590.2018.1445219>



Published online: 28 Feb 2018.



Submit your article to this journal [↗](#)



Article views: 3



View related articles [↗](#)



View Crossmark data [↗](#)

First data on *in vitro* fertilization and blastocyst formation after intraovarian injection of calcium gluconate-activated autologous platelet rich plasma

E. Scott Sills^{a,b}, Natalie S. Rickers^a, Xiang Li^{a,c} and Gianpiero D. Palermo^d

^aOffice for Reproductive Research, Center for Advanced Genetics, Carlsbad, CA, USA; ^bApplied Biotechnology Research Group, University of Westminster, London, UK; ^cData Analytics, Paralian Technology, Inc, Mission Viejo, CA, USA; ^dCenter for Reproductive Medicine & Infertility, Weill Medical College of Cornell University, New York, NY, USA

ABSTRACT

Platelets modulate clinically relevant yet incompletely understood tissue regeneration processes, and platelet rich plasma (PRP) has been previously used with some success in various non-reproductive medical contexts. Here, we extended PRP application to ovarian tissue with a view to document impact on ovarian reserve among women attending for infertility treatment. PRP was freshly isolated from patients ($n=4$) with diminished ovarian reserve as determined by at least one prior IVF cycle canceled for poor follicular recruitment response or estimated by serum AMH and/or FSH, no menses for ≥ 1 year. Immediately following substrate isolation and activation with calcium gluconate, approximately 5 mL of autologous PRP was injected into each ovary under direct transvaginal sonogram guidance. For each study subject, AMH, FSH, and serum estradiol data were recorded at two-week intervals post-PRP and compared to baseline (pre-PRP) values. In this pilot group, mean (\pm SD) patient age was 42 ± 4 years with infertility duration reported as 60 ± 25 months. Following this protocol of intraovarian PRP administration, increases in serum AMH ($p = .17$), decreases in FSH ($p < .01$), or both, were observed in all cases, sufficient to permit retrieval of 5.3 ± 1.3 MII oocytes. IVF occurred 78 ± 22 (range = 59–110) days after activated PRP injection, and results appeared independent of patient age, infertility duration, baseline platelet concentration or pre-treatment antral follicle count. Each patient had at least one blastocyst suitable for cryopreservation. While autologous PRP has been successfully applied therapeutically to various tissues to accelerate healing and wound repair, this is the first description of direct injection of activated PRP into the human ovary of poor prognosis IVF patients. Evidence of improved ovarian function was noted in all who received intraovarian PRP, possibly as early as two months after treatment. Additional research is needed to clarify (and enhance) which PRP components are responsible for altered ovarian function, and to identify predictive characteristics for patients most likely to benefit from this intervention.

ARTICLE HISTORY

Received 25 January 2018
Accepted 21 February 2018
Published online 27 February 2018

KEYWORDS

Platelet rich plasma; ovary; senescence; fertility potential; stem cells; regeneration

Introduction

Clinical use of platelet concentrates (also termed platelet rich plasma, PRP) is perhaps best known for managing thrombocytopenia to improve hemostasis. However, PRP also includes numerous soluble mediators which orchestrate complex immune responses and tissue regeneration [1]. Closely associated with inflammatory signaling, PRP figures prominently in tissue regeneration and orchestrates a regulatory interplay of cellular migration, extracellular matrix remodeling, cell proliferation, apoptosis, differentiation, and angiogenesis [2] in response to widespread cell damage. Following trauma or local ischemia as with myocardial infarction or stroke, platelets are among the first cells to arrive and, following activation, emit a multitude of biologically active mediators to rectify the tissue insult [3]. Notably, the human ovary is covered by an epithelial monolayer which sustains cyclic ‘injury’ and local tissue repair with each ovulation. While resident stem cells have been thought crucial for the regeneration needed for hemostasis and organ integrity here, the identity and mode of action for these cells remains incompletely characterized. Although recent research has opened a doorway into ovarian stem cell biology [4,5], clinical explorations in this field have thus far been limited.

Notwithstanding the now well-established surgical role of PRP in tissue repair, some researchers have suggested that platelets may contribute to overall organ function as well [6]. As a central problem in many clinical infertility presentations is ovarian senescence and an inexorable decline in oocyte endowment, it seems plausible to consider using autologous PRP in a reproductive context. Particularly since the concept of reduced (or entirely lost) fertility potential associated with ovarian failure is the focus of ongoing research, the possibility of PRP improving the ovarian microenvironment – and even interacting with putative ovarian germline stem cells (GSCs) – warrants serious consideration. Here, we report on autologous activated PRP as applied to human ovaries in an office setting, and provide the first clinical data on IVF cycle characteristics following this intervention.

Methods

Patient selection and intake

After institutional review board approval, the study opened as a registered clinical trial (NCT03178695). Patients over age 35 with at least one ovary, infertility of >1 year duration, at least one

prior failed (or canceled) IVF cycle, or amenorrhea for at least three months were eligible to enroll after providing written informed consent. Exclusion criteria included ongoing pregnancy, current or previous IgA deficiency, ovarian insufficiency secondary to sex chromosome etiology, prior major lower abdominal surgery resulting in pelvic adhesions, anticoagulant use for which plasma infusion is contraindicated, psychiatric disorder that precluded participation in the study (including active substance abuse or dependence), ongoing malignancy, or chronic pelvic pain [7].

Sample preparation

Approximately, 8 mL blood was collected from each participant by peripheral venipuncture using a 21 G butterfly catheter affixed via vacutainer to negative pressure receiving tubes (RegenLab; Mont-sur-Lausanne, Switzerland). Samples were immediately labeled and placed in room-temperature centrifuge set to $1500 \times g \times 5 \text{ min}$ [8]. After centrifugation, the blood was fractionated; red blood cells were trapped under the gel while lower density components stratified above the surface of the separator gel. Less than 3 mL of supernatant (corresponding to relatively platelet-poor plasma fraction) was next aspirated off the top of each column before recapping the vial for gentle tube inversion/resuspension.

PRP activation and intraovarian injection

PRP activation was achieved with calcium gluconate (CG) similar to previously published methods [8,9]. In brief, syringes were used to divide activated PRP samples into two equal portions and maintained at room temperature, then attached to a 35 cm single lumen 17 G needle assembly (Rocket Medical, Washington, UK). This apparatus was modified for office PRP administration by bypassing the falcon tube collection port to allow direct injection into ovarian stroma under transvaginal ultrasound guidance. The ovaries were aligned with the needle guide to avoid intervening vascular or other structures; the needle was quickly advanced without rotation deep into the central ovary. Once tip placement was confirmed, the activated PRP sample was slowly introduced as the needle was retracted across previously traversed ovarian cortex. The final $\sim 1 \text{ mL}$ of sample was deposited just under the ovarian capsule as the needle cleared the ovary. After activated PRP injection was completed bilaterally, careful ultrasound assessment of the pelvis was performed to assure vascular integrity and absence of free pelvic fluid. No sedation or anesthesia was necessary for any ovarian PRP injection; for all study patients this was completed in less than seven minutes. Following the procedure, each patient was asked to remain supine and rest for $\sim 15 \text{ min}$; vital signs were rechecked before home discharge.

Assessment of PRP effectiveness and interval to IVF

All patients underwent periodic testing for serum AMH, estradiol (E_2) and FSH at approximately two-week intervals after ovarian PRP. This study was initially configured to enroll menopausal or peri-menopausal patients where serum FSH and E_2 could be measured randomly, without respect to cycle day. This audit approach required recalibration when some women who were acyclic at study entry, began to menstruate subsequent to ovarian PRP. For such patients, instructions were modified to obtain

laboratory testing on cycle day 2 or 3 (for FSH and E_2) and then two weeks thereafter. This preserved the general cadence of twice monthly assessments for all study participants. As published data on ovarian reserve marker responsiveness following PRP dosing do not yet exist, post-treatment target thresholds for AMH, E_2 or FSH could not be referenced. Nevertheless, when improvements in ovarian reserve (i.e. increased AMH or decreased FSH) were measured on two consecutive tests, patients were advised to commence IVF promptly.

Gonadotropin stimulation, periovulatory trigger, and embryology protocols

All patients underwent controlled ovarian hyperstimulation with a conventional gonadotropin regime [10]. As these IVF cycles were completed at various institutions, differing gonadotropin agents and doses were used for follicular recruitment and triggering. Thus a mixed FSH + hMG protocol was used for some, but not all, study patients (this variance occurred because not all IVF cases were performed at this institution). However, all patients underwent standard IVF management at their respective clinics and no investigational medications or procedures were used. All oocytes collected were fertilized with husband's non-frozen sperm via ICSI; blastocysts generated from all cycles were vitrified according to procedures prevailing at each local clinic. While some patients plan a follow-up (second post-PRP) IVF cycle to increase the number of available blastocysts by 'embryo banking' [11,12], one patient advanced to embryo thaw/transfer without banking instead.

Statistical analysis

Patient data were analyzed with Numbers version 4.3.1 (Apple Inc., Cupertino, CA). For normally distributed data (e.g. patient age), mean and standard deviation were used to describe data location and dispersion. Comparisons across means were evaluated by paired two-tailed Student's *t*-test. By default, confidence level was set at 95% for all analysis.

Results

Mean (\pm SD) patient age in this group was 42 ± 4 years; infertility duration was 60 ± 25 months at enrollment. Since activated PRP injection into the ovaries was conducted with no anesthesia, patients were asked to score their pain perception on a 1–10 scale (1 = minimal discomfort, 10 = extreme pain) immediately after the procedure. All patients reported level 2–3 pain associated with ovarian PRP and none requested any controlled post-injection pain medication. Following this protocol of intraovarian administration of activated PRP, when baseline data were compared mean serum FSH was significantly reduced after treatment from 13.6 (range = 10.8–14.9) mIU/mL to 7.7 (range = 3.3–11.8) mIU/mL; $p < .01$ (see Figure 1). Increased serum AMH, although not statistically significant, was also noted among study patients when pre- and post-PRP measurements were compared, as summarized in Figure 2 (0.38 [range = 0.03–0.78] ng/mL vs. 0.61 [range = 0.03–0.92] ng/mL; $p = .17$). Changes in both FSH and AMH after ovarian PRP injection were non-linear and irregular, but considered as permissive of IVF with non-donor oocytes. Mean total gonadotropin dose consumed during IVF in this cohort was $4163(\pm 675)$ IU, and terminal serum estradiol prior to

trigger was $764 (\pm 372)$ pg/mL. A summary of clinical factors observed in this study group is presented in Table 1.

Further analysis was performed to identify factors which might correlate or predict response to ovarian PRP injection. Specific parameters studied in this sub-analysis were baseline platelet concentration, patient age, body mass index (BMI), as well as serum AMH and FSH. Here, only BMI at study entry appeared to correlate strongly ($r = -0.99$; 95% CI) with observed changes in FSH following activated PRP use (see Figure 3). No other pairs tested were found to be significant at the 95% confidence level.

Oocyte yield in this group ranged from 4 to 7 eggs/patient after intraovarian injection of activated PRP. Although the duration of follicular recruitment to achieve this was coincidentally 10 days for all patients, the gonadotropin regimes and type of periovulatory trigger selected were not identical. ICSI was used

in all cases; $2pn$ status was confirmed in 4.2 ± 0.84 zygotes within 24 h of oocyte retrieval. Mean \pm SD partner age was 45.2 ± 10 years in this cohort. No abnormalities were noted in the standard semen analysis in any patient; sperm chromatin structure analysis was not performed for these partners, so no data on nuclear DNA fragmentation were available for study. All four patients had at least one day five blastocyst available for cryopreservation. Frozen embryo transfers are planned for all patients, however most will repeat IVF with a view towards 'embryo banking'. One patient (Case 1) elected not to do this, instead proceeding to embryo thaw/transfer and currently has a singleton pregnancy at 9 weeks gestational age. None of the patients experienced any complications from controlled ovarian hyperstimulation, trigger, or oocyte retrieval.

Discussion

Several innovative approaches to assuage the age-associated decline of ovarian reserve have now moved away from theoretical and toward clinical application. Such techniques as laparoscopically retrieved cortical tissue sample and autologous reimplantation to the ovary, stem cell transfer to the ovary [13], and intraovarian PRP injection to the ovary appear promising; thus far no complications have been reported from these interventions and a few pregnancies have been achieved [13,14].

PRP has a role in tissue regeneration by way of clinically relevant but still poorly understood processes controlling apoptosis, cell survival, and tissue repair or rescue. The novel application of PRP in a reproductive context was pioneered by Pantos et al. [14]. In that report, a group of eight poor prognosis infertility patients underwent laparoscopic intraovarian injection of PRP followed by IVF, resulting in healthy livebirths after thawed embryo transfer derived from non-donor oocytes. Although the

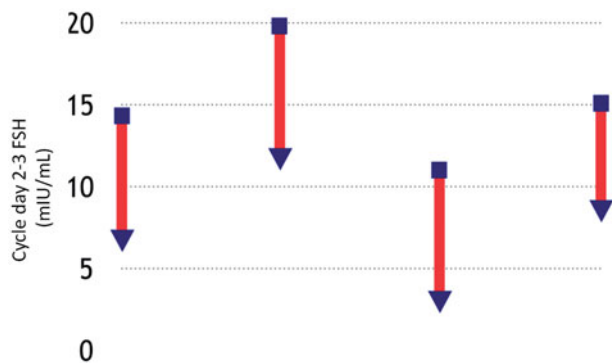


Figure 1. Serum FSH response as recorded before (square) and after (triangle) intraovarian infusion of activated autologous platelet rich plasma for four IVF patients. Corresponding serum estradiol measured was <80 pg/mL for all women ($n = 4$).

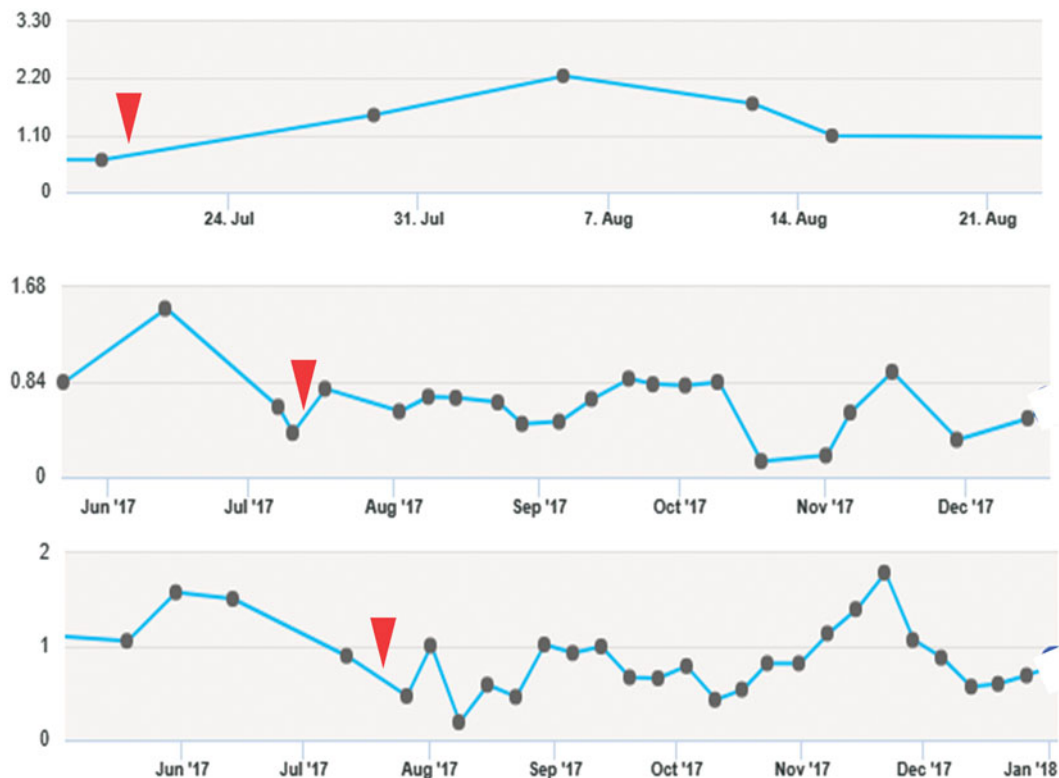


Figure 2. Observed changes in serum AMH following intraovarian infusion of activated autologous platelet rich plasma (arrow). Note: data not shown for one poor prognosis IVF patient for whom AMH never exceeded the lower threshold measurement limit for AMH (0.03 ng/mL), either before or after ovarian PRP dosing.

Table 1. Selected clinical and laboratory features observed in four poor-prognosis IVF patients before and after intraovarian infusion of activated platelet rich plasma (PRP), and subsequent cycle performance in non-donor IVF treatment.

Case	Age (years)	Baseline (pre-PRP)				Pre-PRP AFC		Post-PRP			Post-PRP IVF			
		PLT	AMH	FSH	E ₂	R	L	AMH	FSH	E ₂	PRP interval (days)	GND	E ₂	MII
1	42.3	239	0.09	14	68	3	3	0.66	6.8	122	69	3150	1183	5
2	36.5	222	0.62	19.8	70	4	3	0.92	11.8	29	59	4500	934	5
3	43	250	0.78	10.8	117	5	5	0.84	3.3	49	74	4500	330	7
4	46	225	0.03	14.9	176	4	2	0.03	9.0	23	110	4500	610	4
\bar{X}	42.0	234	0.38	14.9	108	4.0	3.3	0.61	7.7	55.8	78	4163	764.3	5.3
(\pm SD)	4.0	13	0.38	3.7	51	0.8	1.3	0.40	3.6	45.5	22	675	373	1.3
<i>p</i>								.17	<.01	.30				

PLT: platelet count (K); AMH: anti-Müllerian hormone (ng/mL); FSH: follicle stimulating hormone (mIU/mL); E₂: estradiol (pg/mL); AFC: antral follicle count; GND: total gonadotropin dose consumed during IVF cycle (IU); MII: metaphase II oocytes retrieved [after 10 d follicular recruitment].

p Values pre- vs. post-PRP calculated by Student's *t*-test.

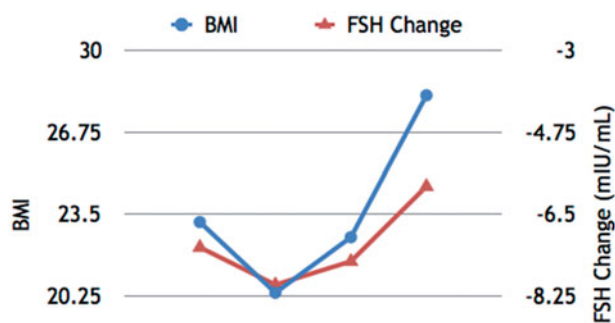


Figure 3. Relation between baseline BMI and Δ FSH as observed in poor-prognosis IVF patients ($n = 4$) following intraovarian infusion of activated autologous platelet rich plasma. Improved (reduced) serum FSH was significantly correlated to lower BMI in this group (-0.99 , by Pearson's *r*).

precise mechanism of PRP to 'rejuvenate' the ovary was incompletely developed, the implications of this treatment for conventional paradigms of reproductive aging and clinical IVF practice were immediately recognized. While many unanswered questions remain, the current study extends the initial report on ovarian PRP by describing a modified (activated) PRP protocol administered in an office setting under transvaginal ultrasound guidance, and detailing subsequent IVF cycle characteristics.

The activated PRP substrate explored in the current study is known to be comprised of cytokines, chemokines, and growth factors including stromal cell derived factor 1 (SDF-1) and hepatocyte growth factor (HGF) which control recruitment, proliferation, and activation of fibroblasts, neutrophils, monocytes and other cells central to wound healing. Within the human ovary, PRP would also be expected to deliver mediators regulating angiogenesis and tissue perfusion which might serve an independent or accessory role in improving oocyte competency [15]. Platelet alpha granules [16,17] are known to release transforming growth factor beta isoform 1 (TGF- β 1), a prime regulator of cell proliferation, angiogenesis, and extracellular matrix deposition [18]. The balance between apoptosis and cell survival is thus governed by PRP components, which release both proapoptotic (Fas-L, CD40L, TRAIL, TWEAK, and LIGHT) and antiapoptotic (HGF, SDF-1, serotonin, adenosine diphosphate, and sphingosine-1-phosphate) signals. High-mobility group protein B₁ (HMGB1) is a 'danger signal' that is exported to the cell surface by platelets upon activation, modulating apoptosis as well as autophagy as a function of local redox status [19].

The changes observed in ovarian reserve after PRP treatment here are difficult to interpret. Fundamentally, any alteration in ovary function associated with insertion of this wide array of cell

signals could have occurred for at least two reasons. One scenario is that oocytes we recovered within several weeks of ovarian PRP administration were actually there all along, always present but latent, and simply awakened with the arrival of numerous cellular growth factors generated by a small bolus of autologous platelets in tandem with standard gonadotropins. An alternate possibility is that growth signals associated with PRP established communication with uncommitted ovarian stem cells, and provided the proper milieu required to induce differentiation to develop *de novo* oocytes.

This latter scenario would require postnatal oogenesis in the human ovary – a controversial concept where several experts have contributed both in favor [20–24] and against [25,26]. As the initial work challenging the notion of irreversible decline of ovarian reserve due to a fixed number of oocytes at birth [20] has been followed by confirmatory research [27], persuasive evidence exists to support the presence of ovarian germ cells capable of generating *de novo* oocytes. Indeed, any residual conflict regarding the existence of ovarian stem cells may now largely center on technical points involving identification and isolation protocols [28,29], rather than the existential question of whether or not human ovarian stem cells are present within the adult ovary [30]. In any case, considerable additional investigation is planned to explore and disentangle these issues, aiming to provide a better understanding of how the ovary behaves following PRP dosing.

This study is limited by several factors, including small sample size, the absence of a placebo control group, and variance in gonadotropin regimes used for IVF after activated PRP dosing. However, comparative study of different stimulation protocols in IVF was beyond the scope of this research. The finding that all patients here succeeded in producing embryos suitable for cryopreservation or transfer, irrespective of what medications were chosen for follicular recruitment or trigger, tends to suggest that pharmacological factors may not matter much when IVF clinics use the protocols most familiar to them.

In this report, observable clinical and laboratory events following intraovarian injection of activated PRP – the first as an office procedure without anesthesia – are presented. Study patients were selected because they were considered very poor prognosis, as all had been classified as refractory cases and referred for donor oocyte IVF elsewhere. Against this background, it was proposed that the tissue repair processes associated with PRP [31] might generalize to the ovary, and our preliminary findings appear to validate this hypothesis. Yet even when this was achieved, the downstream intraovarian effects resulting from stromal/cortical PRP delivery are complex and

require better characterization against a broader metabolic landscape. For example, the previously unknown relation between BMI and observed change in ovarian reserve after PRP was surprising and warrants further study. Mechanisms of action for (and cross-signaling among) platelet-derived mediators have not been fully elucidated with regard to PRP in the ovary – or elsewhere. More generally, years may pass between expert reviews of fertility preservation strategies and formal synthesis of findings [32]. Hence the current results bring renewed urgency to accelerate research in this area, including screening to help predict which patients are appropriate candidates for ovarian PRP treatment.

Disclosure statement

None of the authors report any conflict of interest with this research.

References

- Nurden AT. Platelets, inflammation and tissue regeneration. *Thromb Haemost* 2011;105(Suppl.1):S13–S33.
- Gurtner GC, Werner S, Barrandon Y, Longaker MT. Wound repair and regeneration. *Nature* 2008;453:314–21.
- Stellos K, Kopf S, Paul A, et al. Platelets in regeneration. *Semin Thromb Hemost* 2010;36:175–84.
- Tilly JL, Sinclair DA. Germline energetics, aging, and female infertility. *Cell Metab* 2013;17:838–50.
- Ng A, Barker N. Ovary and fimbrial stem cells: biology, niche and cancer origins. *Nat Rev Mol Cell Biol* 2016;16:625–38.
- Lacci KM, Dardik A. Platelet-rich plasma: support for its use in wound healing. *Yale J Biol Med* 2010;83:1–9.
- Inovium Ovarian Rejuvenation Trials (2017): U.S. National Library of Medicine. Available from: <https://clinicaltrials.gov/ct2/show/NCT03178695> [last accessed 15 Dec 2017].
- Gkini MA, Kouskoukis AE, Tripsianis G, et al. Study of platelet-rich plasma injections in the treatment of androgenetic alopecia through a one-year period. *J Cutan Aesthet Surg* 2014;7:213–19.
- Vahabi S, Yadegari Z, Mohammad-Rahimi H. Comparison of the effect of activated or non-activated PRP in various concentrations on osteoblast and fibroblast cell line proliferation. *Cell Tissue Bank* 2017;18:347–53.
- Sills ES, Schattman GL, Veeck LL, et al. Characteristics of consecutive in vitro fertilization cycles among patients treated with follicle-stimulating hormone (FSH) and human menopausal gonadotropin versus FSH alone. *Fertil Steril* 1998;69:831–5.
- Orris JJ, Taylor TH, Gilchrist JW, et al. The utility of embryo banking in order to increase the number of embryos available for preimplantation genetic screening in advanced maternal age patients. *J Assist Reprod Genet* 2010;27:729–33.
- Kushnir VA, Barad DH, Albertini DF, et al. Effect of Embryo Banking on U.S. National Assisted Reproductive Technology Live Birth Rates. *PLoS One* 2016;11:e0154620.
- Pellicer A. IVI achieves four pregnancies in women with ovarian failure thanks to ovarian rejuvenation. IVI Press release, 2017 May 10. Available from: <https://ivi-fertility.com/notes/ivi-achieves-four-pregnancies-in-women-with-ovarian-failure-thanks-to-ovarian-rejuvenation/> [last accessed 15 Jan 2018].
- Pantos K, Nitsos N, Kokkali G, et al. Ovarian rejuvenation and folliculogenesis reactivation in peri-menopausal women after autologous platelet-rich plasma treatment. Abstracts, ESHRE 32nd Annual Meeting; 3–6 Jul 2016; Helsinki, Finland. *Hum Reprod* 2016 (Suppl. 1):i301.
- Szafarowska M, Jerzak M. Ovarian aging and infertility. *Ginekol Pol* 2013;84:298–304.
- Mannaioni PF, Di Bello GM, Masini E. Platelets and inflammation: role of platelet-derived growth factor, adhesion molecules and histamine. *Inflamm Res* 1997;46:4–18.
- Anitua E, Andía I, Ardanza B, et al. Autologous platelets as a source of proteins for healing and tissue regeneration. *Thromb Haemost* 2004; 91:4–15.
- Lee KS, Wilson JJ, Rabago DP, et al. Musculoskeletal applications of platelet-rich plasma: fad or future? *AJR Am J Roentgenol* 2011;196: 628–36.
- Hu X, Wang C, Rui Y. An experimental study on effect of autologous platelet-rich plasma on treatment of early intervertebral disc degeneration. *Zhongguo Xiu Fu Chong Jian Wai Ke Za Zhi* 2012;26:977–83.
- Johnson J, Canning J, Kaneko T, et al. Germline stem cells and follicular renewal in the postnatal mammalian ovary. *Nature* 2004; 428:145–50.
- Bhartiya D, Sriraman K, Parte S. Stem cell interaction with somatic niche may hold the key to fertility restoration in cancer patients. *Obstet Gynecol Int* 2012;2012:921082.
- Virant-Klun I, Stimpfel M, Skutella T. Stem cells in adult human ovaries: from female fertility to ovarian cancer. *Curr Pharm Des* 2012; 18:283–92.
- Woods DC, White YA, Tilly JL. Purification of oogonial stem cells from adult mouse and human ovaries: an assessment of the literature and a view toward the future. *Reprod Sci* 2013;20:7–15.
- Bukovsky A. Ovarian stem cell niche and follicular renewal in mammals. *Anat Rec (Hoboken)* 2011;294:1284–306.
- Zhang H, Zheng W, Shen Y, et al. Experimental evidence showing that no mitotically active female germline progenitors exist in postnatal mouse ovaries. *Proc Natl Acad Sci USA* 2012;109:12580–5.
- Byskov AG, Hoyer PE, Andersen CY, et al. No evidence for the presence of oogonia in the human ovary after their final clearance during the first two years of life. *Hum Reprod* 2011;26:2129–39.
- White YA, Woods DC, Takai Y, et al. Oocyte formation by mitotically active germ cells purified from ovaries of reproductive-age women. *Nat Med* 2012;18:413–21.
- Bhartiya D. The continued presence of stem cells and oogonia in the adult mammalian ovary. *Hum Reprod* 2012;27:938.
- Telfer EE, Albertini DF. The quest for human ovarian stem cells. *Nat Med* 2012;18:353–4.
- Bhartiya D, Singh J. FSH-FSHR3-stem cells in ovary surface epithelium: basis for adult ovarian biology, failure, aging, and cancer. *Reproduction* 2015;149:R35–48.
- Roubelakis MG, Trohatou O, Roubelakis A, et al. Platelet-rich plasma (PRP) promotes fetal mesenchymal stem/stromal cell migration and wound healing process. *Stem Cell Rev Rep* 2014;10:417–28.
- Martinez F. International Society for Fertility Preservation – ESHRE – ASRM Expert Working Group. Update on fertility preservation from the Barcelona International Society for Fertility Preservation-ESHRE-ASRM 2015 expert meeting: indications, results and future perspectives. *Fertil Steril* 2017;108:407–15.e11.